

# Scientific Report

Natural topical solutions  
in multimodal management  
of animal skin disorders

**Our deep gratitude to following veterinarians having participated in different clinical studies:**

Drs. F. Banovic, E. Bensignor, S. Bettenay, P. Bourdeau, M-C. Cadiergues, A.M. Cordero, C. Darmon-Hadjaje, V. Fadok, O. Fantini, K. Glos, M. Mosca, R.S. Mueller, M. Nagata, A. Neuber, Ch. Noli, A. Oliveira, T. Olivry, A. Patterson, D. Pin, C. Pressanti, C. Romero, W. Rosenkrantz, G. Sheinberg, C. Tamamoto-Mochizuki, E. Vidémont, all boarded dermatologists from ACVD, AiCVD, LACVD or ECVD and Dr. A. Rodrigues-Hoffmann boarded pathologist from ACV Pathology.

Drs. M. Blaskovic, A. Bouvier, M. Catarino, B. Dominguez, L. Fabriès, E. Gaillard, R. Heredia, S. Lawhon, C. Meason-Smith, P. Mimouni, R. Ocana, C. Older, H. Pouliquen, C. Sauter-Louis, F. Seckerdiek, S. Treffer, T. Toomet, W. Von Bornhard, J. Wu.

---

21 years of research

---

### 03 | Canine allergic dermatitis including atopic dermatitis (CAD)

- 04** | Use of natural topicals with essential fatty acids in combination with lokivetmab in the management of canine atopic dermatitis - Drs. E. Bensignor & E. Vidémont
- 05** | Performance of a natural complex in a reconstructed canine epidermis model stressed by cytokines - Dr. C. Darmon-Hadjaje *et al.*
- 06** | Protective effect of a spot-on in a model of cutaneous barrier altered by tape stripping - Pr. D. Pin & Dr. M. Mosca - 2015 Guidelines of ICADA
- 07** | Effect of a soothing spray on dogs with moderate atopy - Dr. S. Tretter & Pr. R.S. Mueller  
A case of iatrogenic hyperadrenocorticism - Pr. M-C. Cadiergues
- 08** | Hydrating effect of a fluid cream on intact and damaged skin - Dr. O. Fantini & Pr. Pin
- 09** | Interest of a cleansing and soothing foam in CAD - Drs. E. Bensignor & L. Fabriès

### 10 | Skin prone to microbial imbalances & otitis externa

- 11** | Efficacy of a purifying spray and a purifying ear cleanser on biofilms - Dr. E. Bensignor *et al.*
- 12** | Efficacy of a spray associated with an antibiotic in the multimodal management of canine superficial pyoderma - Dr. E. Bensignor *et al.*
- 13** | Efficacy of a purifying ear cleanser - Dr. C. Pressanti & Pr. M-C. Cadiergues
- 14** | Efficacy of a spot-on in dogs prone to superficial pyoderma relapses - Dr. V. Fadok *et al.*
- 15** | Efficacy of natural topicals compared to a chlorhexidine-based shampoo on superficial pyoderma in dogs - Drs. G. Sheinberg & A.M. Cordero *et al.*

### 16 | Kerato-seborrheic disorders

- 17** | Characterization of the cutaneous microbiota of malodor dogs and effect of a spot-on on the skin microbiota - Dr. C. Meanson Smith, Pr. A. Rodrigues Hoffmann *et al.*
- 18** | A case of sebaceous adenitis and mural folliculitis in a cat - Drs. K. Glos, S. Bettenay, Pr. R.S. Mueller *et al.*
- 18** | A case of autosomal recessive congenital ichthyosis in a dog - Dr. Tamamoto-Mochizuki, Pr. T. Olivry *et al.*
- 19** | Open study on the efficacy of a spot-on in case of kerato-seborrheic disorders - Dr. E. Bensignor *et al.*

### 20 | Hyperkeratinization - nose, calluses, pads

- 21** | Protective and repairing efficacy of a natural balm on paws of sled dogs - Dr. A. Bouvier, Pr. P. Bourdeau *et al.*
- 22** | Control of idiopathic nasal hyperkeratosis in dogs with a natural balm - Dr. M. Catarino, Pr. M-C. Cadiergues *et al.*
- 23** | Non-infected calluses in dogs - Dr. E. Gaillard, Pr. M-C. Cadiergues *et al.*

# Allergic dermatitis including Canine Atopic Dermatitis (CAD)

## Canine atopic dermatitis (DAC)

is a genetic chronic skin disease. This common disease is also one of the main reasons for consultation in veterinary dermatology. An efficient treatment is always multimodal, such as:

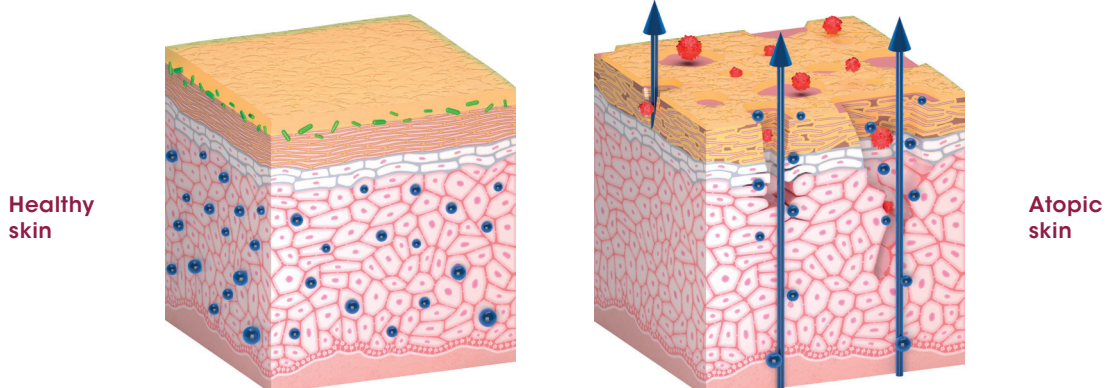
- 1 | Specific desensitization if the allergy has been identified,
- 2 | Reduction of skin inflammation by immunomodulatory, anti-allergic and topical or systemic antipruritic agents,
- 3 | Skin rehydration and skin barrier repair.

Skin barrier repair is particularly important in both short and long terms by rapidly improving the cosmetic appearance of the skin and fur to the owners' satisfaction while reducing allergen penetration, breaking the vicious circle of itchiness/scratching and limiting the TEWL in the long run.

Atopic skin is an allergic skin in need of specific care. Frequent, repeated and regular use of topical soothing moisturizers is always highly recommended.

During inflammatory phases, spot-on treatment, shampoos, lotions or foams containing active ingredients with proven anti-allergic properties are preferable. During chronic phases, hydrating products are useful and recommended.

From "Handbook of Veterinary Dermo-Cosmetics"  
by Dr. E. Bensignor et Dr. E. Vidémont Med'Com 2016



In most skin diseases, barrier integrity is at stake when skin disorders occur. Clinical evidences demonstrate how topical dermo-cosmetic formulations, specifically designed for dogs and cats, can help repair skin barrier.

Based on natural ingredients, all Dermoscent® products are rich in plant-derived essential fatty acids (Omega 6 & Omega 3), combined with specifically conceived synergies of essential oils along with other high-quality natural ingredients.



## Use of natural topicals with essential fatty acids in combination with lokivetmab in the management of canine atopic dermatitis

Dr. E. Bensignor\* and Dr. E. Vidémont\*  
\*ECVD dipl.

Article published in **Veterinary Dermatology** (2022); 33(1): 68-e22 and poster presented at **2020 WCVD congress**.

### OBJECTIVE

The aim of this prospective study is to evaluate the effect of combining dermo-cosmetic products (ATOP 7®; Dermoscent®, LDCA) with the administration of lokivetmab (Cytopoint®; Zoetis) to promote a better improvement in the clinical signs of CAD and help prolong the period between episodes.

### MATERIALS AND METHODS

The study was single-blinded and controlled. Thirty atopic dogs were included in the study and randomly divided into two groups:

- One group received an injection of lokivetmab (Cytopoint®; Zoetis, 1 mg/kg SC)
- One group received an injection of lokivetmab (Cytopoint®; Zoetis, 1 mg/kg SC) as well as ATOP 7® spot-on and ATOP 7® Shampoo, composed of plant-extracted essential fatty acids, ceramides and soothing ingredients, once a week for 4 weeks.

The evaluation was based on 3 criteria: a pruritus score (VLAS), a CADLI score (Canine Atopic Dermatitis Lesion Index) and a cosmetology score comprising a scale to evaluate the appearance of the coat, the dryness/hydration of the skin, dandruff and odor. Finally, owner and investigator satisfaction was assessed. Dogs were followed up at 10, 17, 31 days after injection and a final follow-up visit was done when a relapse requiring a second injection of lokivetmab occurred.

### RESULTS

Twenty-eight dogs completed the study, two dropped out due to COVID-19 lockdown. No side effects were reported.

At D31, both groups presented a satisfactory evolution with a significant improvement ( $p < 0.001$ ) of the 3 scores: pruritus, CADLI and cosmetology compared to D0.

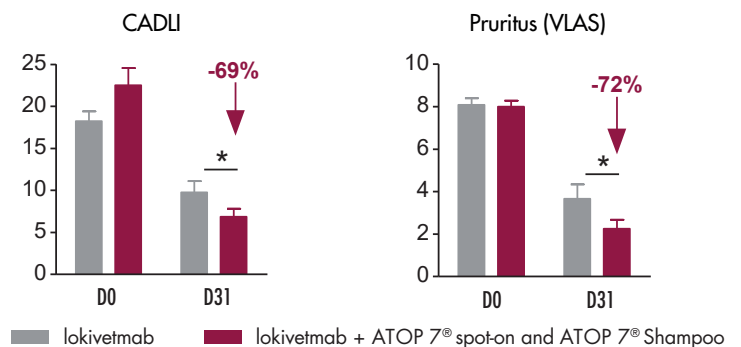
**There was a greater improvement in these parameters in the group that received ATOP 7® topicals combined with the injection of lokivetmab: a 69% reduction in the CADLI score in this group versus 47% in the group that received lokivetmab**

alone ( $p < 0.05$ ); reduction of the pruritus score by 72% vs 55% in the lokivetmab alone group ( $p < 0.05$ ); improvement of the cosmetology score by 67% vs 35% in the lokivetmab alone group ( $p < 0.001$ ). This difference was confirmed by the owners' and investigators' satisfaction scores, which were higher in the group that received lokivetmab combined with topicals.

In addition, the leadtime between the two lokivetmab injections was prolonged by 4.3 days in the group that received topicals combined with the injection: 37.5 days vs. 33.2 days ( $p < 0.05$ ).

### CONCLUSION

In this study, treatment with lokivetmab in combination with a spot-on and a shampoo containing essential fatty acids and other natural ingredients promoted skin barrier repair, which may have contributed to the improvement in pruritus and CADLI scores compared to the use of lokivetmab alone. In addition, the study suggests a sparing effect. Thus, combining lokivetmab with topical treatments that contribute to skin barrier repair is of interest in the multimodal approach to the management of CAD. This confirms the value of complementary care in dogs, which is widely recommended in the management of human atopic dermatitis.



Statistical significance \*  $p < 0.05$

# Performance of a natural complex in a reconstructed canine epidermis model stressed by cytokines



Drs. C. Darmon-Hadjaje\*, N. Amalric,  
J. Dellacasagrande

\*ECVD dipl.

Abstract published in **Veterinary Dermatology** (2021); 32: p. 425.  
Short Communication presented at **2021 ESVD congress** and poster  
presented at **2021 AFVAC congress**.

## INTRODUCTION

The recent development of reconstructed canine epidermis (RCE) models enables to mimic *ex vivo* canine atopic dermatitis in order to study the efficacy of active ingredients at the epidermis level. In this study, the complex of natural active ingredients (vegetable oils, essential oil synergy, phyto-ceramides, etc.) of ATOP 7<sup>®</sup> spot-on was evaluated.

## MATERIALS AND METHODS

Epidermis (RCE) were produced by using keratinocytes collected from healthy dogs. A cocktail of cytokines was used to simulate barrier defects, thus creating epidermis similar to those observed in atopic dermatitis (RCE-AD). The epidermis were treated with the 0.02% active complex and compared to RCE untreated or treated with 0.5µM of tofacitinib, a selective Janus Kinase (JAK) inhibitor. RCE morphology was assessed by histological staining with Haemalun-Eosin, filaggrin expression by immunofluorescence and inflammation by ELISA assay of the pro-inflammatory marker interleukin-8 (IL-8). Three epidermis were analyzed per condition.

## RESULTS

**Tolerance:** The good tolerance of the complex was confirmed by histology since no morphological changes of the RCE were observed.

**Efficacy:** RCE-AD showed structural disorganization with cell dissociation (spongiosis) and a decrease in the number of keratohyalin grains.

Treatment with the natural complex limited the effects of cytokines by reducing spongiosis and increasing the number of keratohyalin grains (fig. 1). The expression of pro-filaggrin and filaggrin, a key protein in epidermal differentiation and hydration, was decreased in RCE-AD and the natural complex increased its expression by +52%. Furthermore, RCE-AD showed an increase in IL-8 secretion and the reference molecule (tofacitinib) allowed a 46% decrease in the level of IL-8, while the natural complex allowed a remarkable decrease of 25% (fig. 2).

## CONCLUSION

The tested complex presents a good tolerance and shows a beneficial effect on the morphology of stressed epidermis, limiting spongiosis and thus promoting cell cohesion. In addition, the complex allows an improvement in the expression of filaggrin, suggesting a beneficial effect on the differentiation and hydration of the epidermis. Finally, the natural complex induces a marked decrease in the level of the pro-inflammatory cytokine measured. These results should be confirmed *in vivo*.

Fig. 1: Morphological analysis

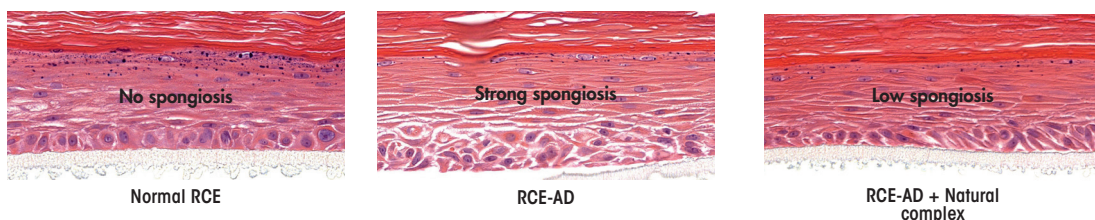
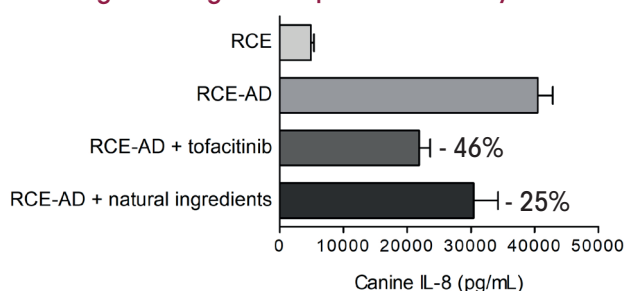


Fig. 2: Dosage of the pro-inflammatory marker IL-8



TAPE STRIPPING MODEL



Skin barrier effect of a spot-on in a model of cutaneous barrier altered by tape stripping

Pr. D. Pin\* and Dr. M. Mosca\*

\*ECVD dipl.

Article published in **Veterinary Sciences** (2022); 9: p.390 and poster presented at **2021 ESVD congress**.

INTRODUCTION

This pilot study was specifically designed to evaluate the effect of ATOP 7® spot-on on the skin barrier in a non-invasive model of acute skin barrier rupture by tape stripping.

MATERIALS AND METHODS

The study was conducted on 5 healthy 3.5-year-old Beagle dogs with no skin condition and having received no systemic or topical treatment in the previous 3 months (excluding internal antiparasitics). The model of skin barrier disruption by delamination of the *stratum corneum* is based on the repeated application of a fixed number of pieces of tape to clipped skin on the back at 4 sites, one each week (Z1-4)(fig. 1). The method is controlled and the dog is its own control (Z1). The spot-on is applied once a week for 3 weeks on the same point, in the centre of the 4 tape stripping zones.

The intensity of the alteration of the skin barrier induced by the tape stripping is evaluated by measuring the Trans-Epidermal Water Loss (TEWL, AF200Aquaflux®), each week after the delamination, successively on 3 zones (Z2, Z3, Z4) and

compared to the control zone (Z1, before application of the spot-on) and to an area of non-delaminated skin.

RESULTS

While tape stripping induces a strong increase in the TEWL (D1,  $p < 0.001$ ), the application of the spot-on gradually limits the TEWL after delamination, with a TEWL comparable to that of the healthy area after the 3<sup>rd</sup> application (D22, non-significant difference vs. healthy skin - fig. 2). Moreover, the spot-on demonstrates in parallel its diffusion efficiency on different areas, at a distance from the application point.

CONCLUSION

This study shows that the topical used for 3 weeks limits the Trans-Epidermal Water Loss in case of skin barrier alteration, maintaining it close to the level of healthy skin as early as a few days after the 3<sup>rd</sup> application. The results suggest that repeated and regular use of this spot-on helps to hydrate the skin and protect the skin barrier, giving it better resistance to the aggression caused by the tape stripping method.

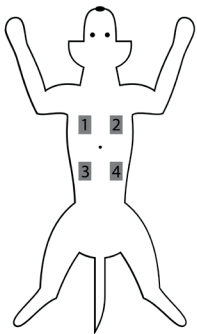
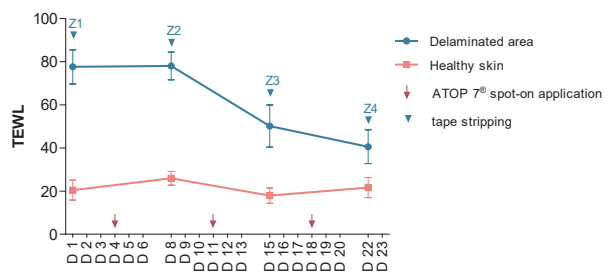


Fig. 1: 4 zones of "tape stripping"

Fig. 2: Trans-Epidermal Water Loss



ICADA 2015

International guidelines for the management of CAD

The **Guidelines issued by ICADA** (International Committee on Allergic Diseases of Animals) stipulated in its 2015 updates the **interest of using a spot-on based on plant-extracted EFA and essential oils to help improve the clinical signs of CAD\***.

Online access to the ICADA Guidelines:

<http://www.biomedcentral.com/1746-6148/11/210>

\*MULTICENTRIC, RANDOMIZED, DOUBLE-BLINDED, PLACEBO-CONTROLLED STUDY – The Veterinary Journal - Dr. M. Blaskovic, Dr. W. Rosenkrantz, Dr. A. Neuber, Dr. C. Sauter-Louis and Pr. R.S. Mueller

# Effect of a soothing spray on dogs with moderate atopy

Dr. S. Tretter and Pr. R. S. Mueller\*  
- University of Munich

\*ECVD dipl.

Article published in **Journal of the American Animal Hospital Association** (July/Aug. 2011); 47(4): p.236-240 and Short Communication presented at **2010 NAVDF congress** in Portland.



## MATERIALS AND METHODS

7 atopic dogs received ATOP 7® Spray once daily during 8 weeks. For ethical reasons, only dogs with moderate CAD were included. Both pruritus and CADESI scores were determined by the clinician before application of the spray (D0) and after 8 weeks (D56).

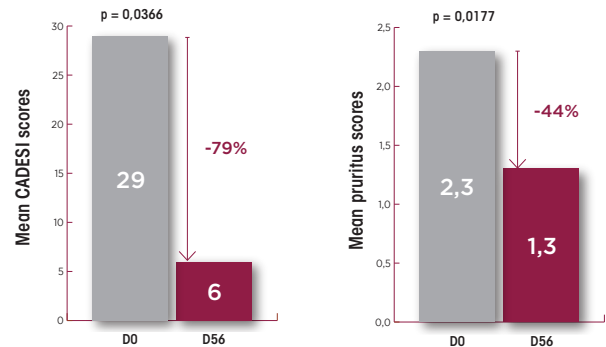
## RESULTS

The CADESI score decreased with a mean of 29 at D0 and 6 at D56 ( $p=0.0366$ ) and the pruritus score was improved from 2.3 to 1.3 ( $p=0.0177$ ).

## CONCLUSION

Atopic dogs that received ATOP 7® Spray for 8 weeks showed significant improvements. ATOP 7® Spray helps repair and soothe atopic skin.

### Score improvement



# A case of iatrogenic hyperadrenocorticism

Pr. M-C. Cadiergues\* - École Nationale Vétérinaire de Toulouse (France)\*ECVD dipl.

## ANAMNESIS AND MEDICAL HISTORY

An 11-year-old intact female Coton de Tuléar was presented in May following a 9-month history of a severe inguinal inflammation with bilateral and pruritic lesions and a marked pedal pruritus.

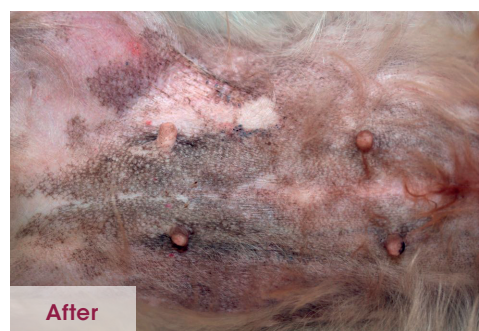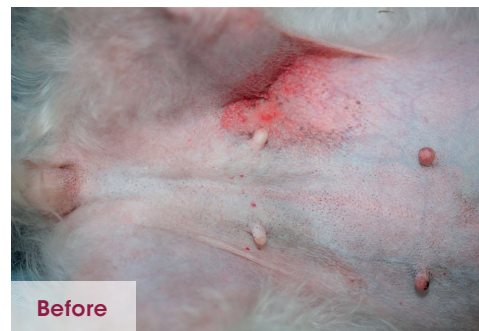After continuous application of dermo-corticosteroids upon the owner's own initiative, the dog presented cutaneous lesions very likely linked to iatrogenic hyperadrenocorticism which were possibly aggravated by local application of prednisolone.

A therapeutic rest (discontinuation of thyroid supplementation and corticoids) was thus opted. ATOP 7® Spray was chosen as a sole topical treatment to be applied twice daily on the lesions.

## RESULTS

After 3 weeks, the owner reported a very positive evolution with resolution of the pruritus. Functional investigation of the adrenal glands with ACTH stimulation resulted in no response so far. ATOP 7® Spray was continued and further complemented with a moisturizer.

5 months after the initial presentation of the dog the general condition was excellent, skin thickness appeared normal. A post-inflammatory hyperpigmentation was generalized to the whole abdomen.



CONTROLLED CLINICAL STUDY



## Hydrating effect of a fluid cream on intact and damaged skin

Pr. D. Pin\* and Dr. O. Fantini\* / Dermatology Unit - Institut Claude Bourgelat - VETAGRO SUP - Lyon (France)

\*ECVD dipl.

### INTRODUCTION

Treatment for skin dryness – also called xerosis – is important as dryness might lead to pruritus which might then lead to lesions or excoriations, exposing the skin to risks of secondary infections. Local symptomatic management through application of topical care to hydrate the skin becomes thus essential.

### MATERIALS ET METHODS

6 healthy adult Beagle dogs are enrolled in the study. One pair of hairless areas is defined as healthy/intact skin and another pair as damaged by tape stripping. For each pair, one side is the control while ATOP 7<sup>®</sup> Hydra Cream is applied on the other side once daily, during 3 days.

The hydration rate of the *stratum corneum* is measured 3 times a day with a corneometer: prior to ATOP 7<sup>®</sup> Hydra Cream application, 2H and 6H after application.

### RESULTS

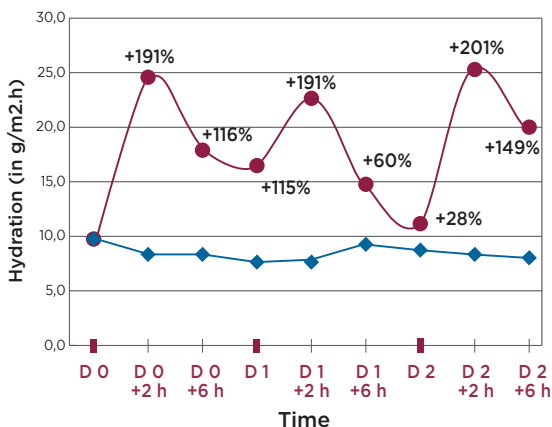
On intact skin in average: +194% of skin hydration after 2H ( $p < 0.05$ ) and +108% after 6H.

On damaged skin in average: +164% of skin hydration after 2H ( $p < 0.05$ ) and +122% after 6H ( $p < 0.05$ ).

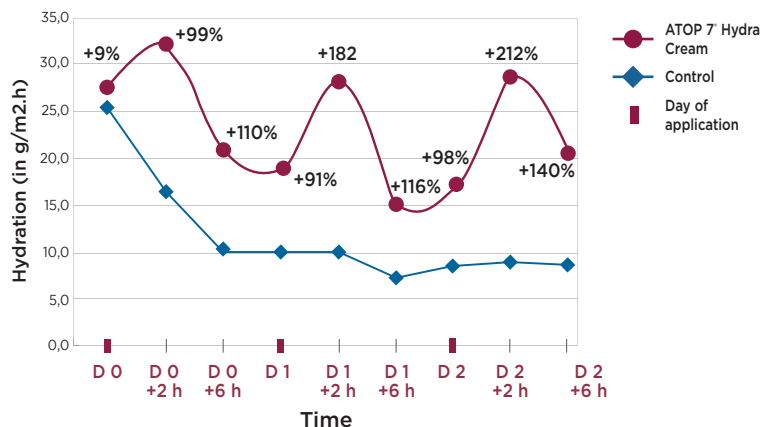
### CONCLUSION

With its long-lasting hydrating effect, ATOP 7<sup>®</sup> Hydra Cream is useful in case of skin dryness.

Evaluation of hydration capacity of ATOP 7<sup>®</sup> Hydra Cream on intact skin



Evaluation of hydration capacity of ATOP 7<sup>®</sup> Hydra Cream on damaged skin



% calculated for each measure by comparing them to the control group. \* $p < 0.05$ ; \*\* $p < 0.01$ ; \*\*\* $p < 0.001$

# Effect of a rinse-free soothing and cleansing foam in canine atopic dermatitis

Dr. E. Bensignor\* and Dr. L. Fabriès

\*ECVD dipl.

Article published in **Veterinary Dermatology** (Oct. 2018); 29(5): p. 446-448 and Short Communication presented at **2018 GEDAC congress** in Chamonix.



## INTRODUCTION

Treatment compliance is an issue for both dogs and humans suffering from AD. Few controlled clinical studies evaluate the interest of topical non-steroidal agents for the treatment of CAD. This study evaluates the interest of ATOP 7<sup>®</sup> Mousse, rinse-free soothing and cleansing foam, in the management of CAD.

## MATERIALS AND METHODS

ATOP 7<sup>®</sup> Mousse was applied twice weekly for 14 days on 8 dogs with mild to moderate CAD. Clinical lesions (CADLI) and pruritus (VLAS) were evaluated by the veterinarian. A cosmetic score (0 = bad to 4 = excellent) was assigned by the veterinarian and the owners according to 3 criteria: appearance of the coat after application, smell of the product and ease of use.

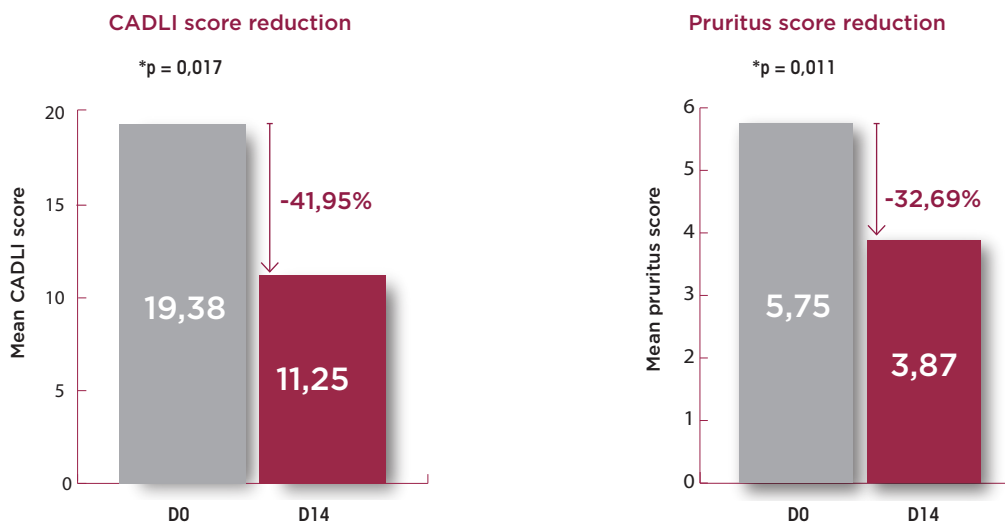
## RESULTS

All dogs completed the study without any adverse effect reported. There was a significant diminution of the CADLI score of -41.95% (p=0.017) and of the pruritus score of -32.69% (p=0.011). Cosmetic characteristics were viewed positively for all criteria with an average score of 3.63 for the odor, 2.88 for the appearance of the coat after product application and 3.25 for product ease of use. Moreover, both the owners and the veterinarian were satisfied with product efficacy.

## CONCLUSION

ATOP 7<sup>®</sup> Mousse has been proven effective to help repair and soothe atopic skins in moderate CAD. With a practical galenic form, the rinse-free foam encourages compliance among owners and can be considered as an option in managing moderate CAD.

Evolution of CADLI and pruritus scores from D0 to D14



# Skin prone to microbial imbalances & otitis externa

## Skin is sterile at birth.

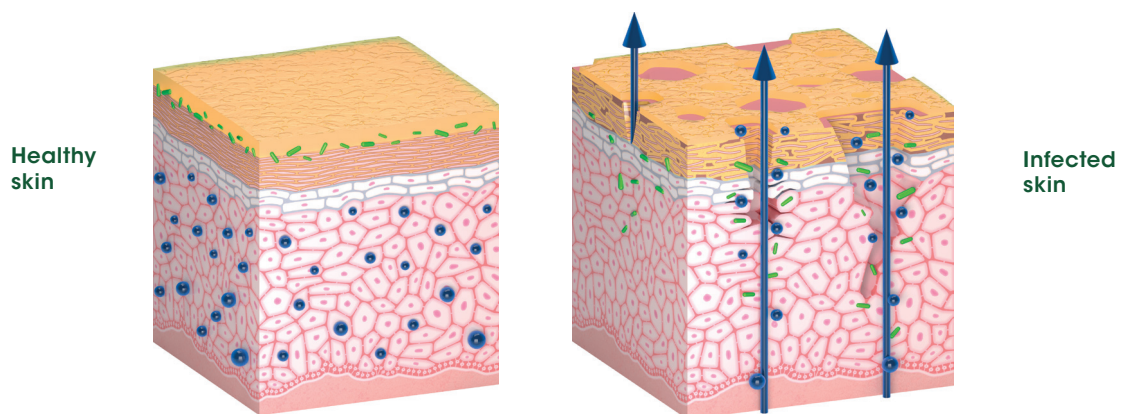
Bacteria colonize the cutaneous surface during birth and the hours following birth. Healthy skin is inhabited by various bacterial species, forming the skin microflora. This is the cutaneous bacterial ecosystem.

While certain bacteria are pathogenic, other species do not cause infection. They are permanently established on the skin where they multiply and prevent the attachment and proliferation of other microorganisms through competing for nutrients and bacterial interference. They are indispensable and beneficial to the body. A good equilibrium of these residential bacteria prevents skin from pyoderma.

The prolonged use of topical antiseptics should not be recommended generally because these substances eliminate the beneficial skin flora and, as a result, render the skin more vulnerable to intrusion of pathogenic species. Several dermo-cosmetic solutions can be used to successfully decrease skin infection risk. They are also good options to complement specific antimicrobial therapies. Various formulations are available such as shampoos, lotions, sprays or spot-on, in order to:

- 1 | Reduce bacterial or *Malassezia* adhesion,
- 2 | Promote natural defense of the skin barrier,
- 3 | Prevent the proliferation of pathogenic microorganisms.

From "Handbook of Veterinary Dermo-Cosmetics"  
by Dr. E. Bensignor and Dr. E. Vidémont Med'Com 2016



# Effects on *S. pseudintermedius*, *M. pachydermatis* and *P. aeruginosa* biofilms

Dr. E. Bensignor\*, C. Feuillolay,  
Dr. L. Fabriès, R. Andriantsalama and C. Roques

\*ECVD dipl.

Abstract published in **Veterinary Dermatology** (Aug. 2019); 30(4): p. 356 and poster presented at **2018 ESVD** in Dubrovnik and **2019 NAVDF** in Austin.



## INTRODUCTION

Biofilm plays an important role in some cases of pyoderma and otitis externa in dogs, as it may contribute to treatment failures and microbial resistance. The aim of this *in vitro* study was to assess the effect of natural topical solutions containing N-acetylcysteine and other natural extracts (propolis, essential oils), on both microbial biofilm formation and already formed biofilms.

## MATERIALS AND METHODS

The ear cleanser was tested on *M. pachydermatis* and *P. aeruginosa* and the topical spray was tested on *S. pseudintermedius*. Sterile water was used as a control.

Assessments were made on biofilm formation in microtiter plates by counting adhered microbial colonies at 24, 30, 48, 54 and 72H. Effects on preformed biofilms were assessed by counting adhered and planktonic microbial colonies at 10, 20, 30, 120 and 240 min and evolution of the structure was visualized with a confocal microscope. Numbers were calculated as log CFU/mL or log CFU/well (CFU = colony-forming unit).

## RESULTS

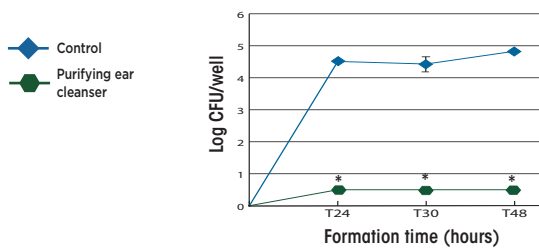
A significant inhibition of biofilm formation ( $*p < 0.05$ ) was demonstrated with a difference of 4.3 log for *M. pachydermatis*, 7.25 log for *P. aeruginosa* and 6.9 log for *S. pseudintermedius*, compared to the control. This activity remained effective for as long as the product was in contact with the microorganisms.

Results obtained on preformed biofilms suggest a disruptive effect on adhered colonies, prior to elimination of planktonic microorganisms. This effect was significant ( $*p < 0.05$ ) on *P. aeruginosa* biofilm with a reduction of 3.7 log of adhered colonies and of nearly 5 log of planktonic colonies after 120 min.

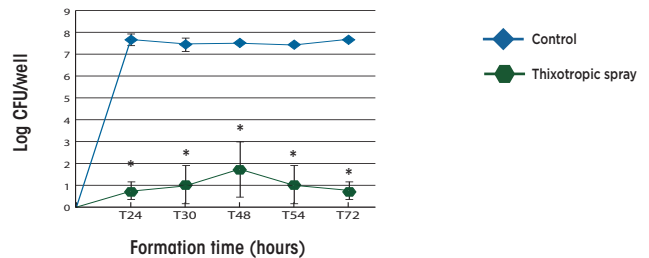
## CONCLUSION

The use of natural topicals can help maintain the balance of microbial ecosystem prior to and during episodes.

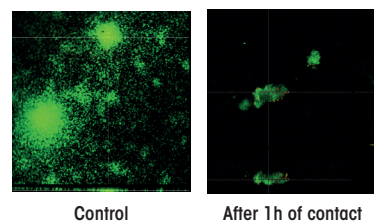
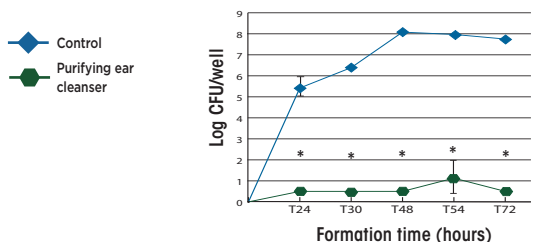
Effect of the purifying ear cleanser on biofilm formation of *M. pachydermatis*



Effect of the purifying ear cleanser on biofilm formation of *S. pseudintermedius*

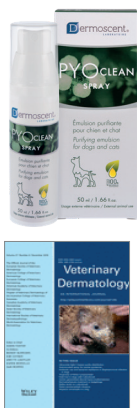

Effect of the purifying ear cleanser on biofilm formation of *P. aeruginosa*



Purifying ear cleanser - Disruptive effect of a *P. aeruginosa* mature biofilm (confocal microscopy observation)

**RANDOMIZED DOUBLE-BLIND PLACEBO-CONTROLLED CLINICAL STUDY**



# Efficacy of a topical associated with an antibiotic in the multimodal management of canine superficial pyoderma

Dr. E. Bensignor\* et al.

\*ECVD dipl.

Poster presented at **2016 WCVD congress** in Bordeaux and article published in **Veterinary Dermatology** (Dec. 2016) 27(6): p. 464-467.

### INTRODUCTION

Bacterial pyoderma is a frequent disease in dogs. Despite widespread availability of effective antibiotics, Good Clinical Practice recommends the avoidance of long-term use of antibiotics to prevent bacterial resistance. The aim of this study was to evaluate the resolution speed of clinical signs of bacterial pyoderma in dogs treated with a systemic antibiotic along with PYOclean® spray, composed of plant-derived essential fatty acids, essential oils and other specific natural ingredients such as N-acetylcysteine with antibiofilm properties.

### MATERIALS AND METHODS

12 dogs with superficial bacterial pyoderma were included and followed-up for 35 days. Both investigator and owners were blinded. All dogs were treated with a systemic antibiotic (cefalexin 15 mg/kg BID) associated randomly with PYOclean® Spray on half of their body and a placebo spray on the other half (each dog was its own control). A clinical and cytological score was calculated at inclusion and each week until resolution of pyoderma.

### RESULTS

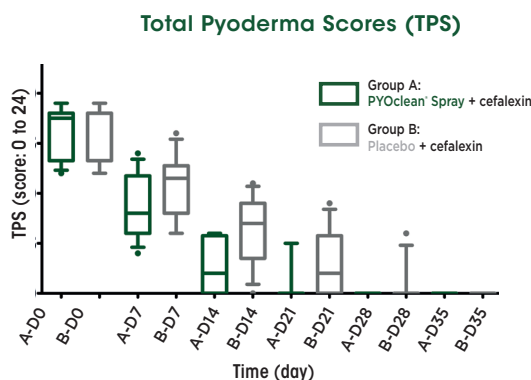
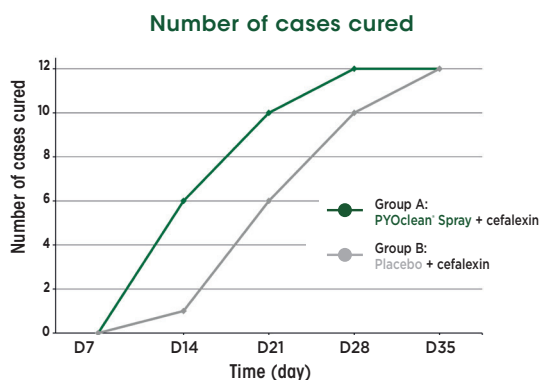
Mean pyoderma scores were significantly reduced ( $p < 0.003$ , Wilcoxon-Signed Rank Test) in both groups:

- **Week 1:** -47% with the association of antibiotic and PYOclean® Spray versus -34% with antibiotic and placebo
- **Week 2:** -83% with the association of antibiotic and PYOclean® Spray versus -60% with antibiotic and placebo
- **Week 3:** -95% with the association of antibiotic and PYOclean® Spray versus -82% with antibiotic and placebo
- **Week 4:** -100% with the combination of antibiotic and PYOclean® Spray versus -96% with antibiotic and placebo

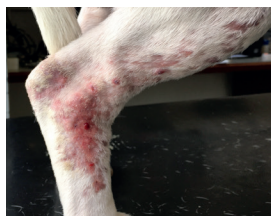Among areas treated with PYOclean Spray® in association with the antibiotic, 50% were completely resolved at week 2, 83% at week 3 and 100% at week 4 compared to respectively 8%, 50% and 83% for the half bodies treated with placebo and the antibiotic. All dogs completed the study without any side effects.

### CONCLUSION

These results suggest the interest of combining PYOclean® Spray with antibiotic treatment in the multimodal management of canine superficial pyoderma.

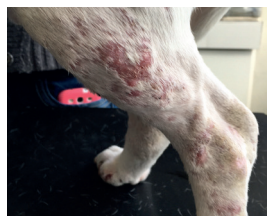

With placebo



D14

With PYOclean® Spray



# Efficacy of a purifying ear cleanser in dogs with canine erythemato-ceruminous external otitis or defects in epithelial migration

Dr. C. Pressanti\* and Pr. M-C. Cadiergues\*, École Nationale Vétérinaire de Toulouse (France)

\*ECVD dipl.

Poster presented at 2012 AFVAC congress in Lyon.



## INTRODUCTION

The present study was conducted to evaluate the *in vivo* efficacy of PYOclean® Oto, an ear cleanser containing essential oil, propolis, and N-acetylcysteine, as a purifying ear cleanser in dogs with erythemato-ceruminous otitis externa (ECOE) or abnormal epithelial migration (AEM).

## MATERIALS AND METHODS

Inclusion criteria were clinical signs of ECOE (erythema and moist, brown, waxy discharge) or AEM in one or both ears.

Exclusion criteria were parasitic otitis, presence of a foreign body, purulent otitis, end-stage proliferative ear disease, occlusive masses, ruptured tympanic membrane, use of systemic or topical antifungal, antibacterial or anti-inflammatory agents or use of an ear cleanser within 2 weeks prior to the study.

The owners were shown how to apply the product on the affected ears by completely filling the ear canal with the solution and massaging the ear base for one minute. The frequency of use was determined by the clinician for each dog and adjusted according to clinical progress. No placebo group was included for ethical reasons. For each ear, clinical and cytological criteria were evaluated. 10 dogs of various breeds between 1 and 11 years old were included. All but 2 had bilateral auricular abnormalities.

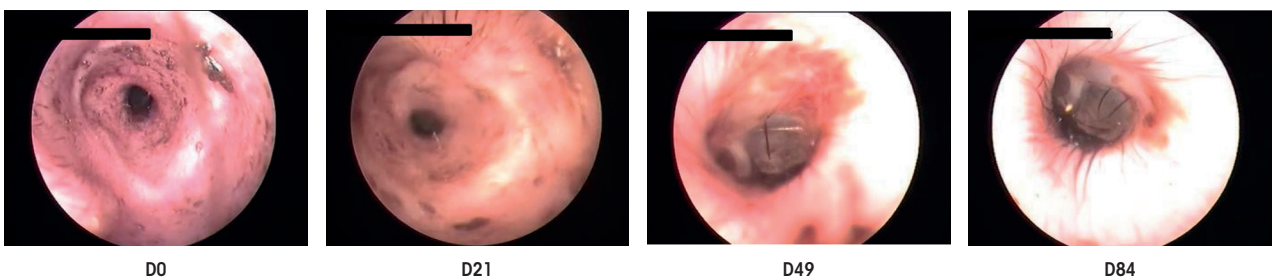
11 ears showed ECOE and 7 had AEM. *Malassezia* overgrowth was present in 8 ears. According to the investigator's decision, PYOclean® Oto was applied daily (2 ears), every other day (5 ears), twice weekly (4 ears), weekly (6 ears) or fortnightly (1 ear). Clinical scores were measured at the initial visit (V1) and final visit (V4) 12 weeks after.

## RESULTS

During the follow-up visits (V2, V3, V4), ear cleanser applications have been spaced out for 14/18 ears. At the end of the study, clinical scores were significantly reduced for epithelial migration, erythema, and total clinical score. *Malassezia* overgrowth was controlled in 5/8 ears. No adverse effect was reported.

## CONCLUSION

This study confirms that thorough and regular ear cleansing is an important therapeutic component in the management of canine otitis externa. Moreover, it also confirms the necessity of clinical assessment (otoscopic examination) and cytological evaluation to follow the progression of the otitis even when a sole ear cleanser is prescribed. The single-dose presentation of PYOclean® Oto ensures that a sufficient volume is applied while preventing cross-contamination between the ears. Additional investigations with controlled studies would be interesting to confirm these promising results.



D0

D21

D49

D84

## RANDOMIZED DOUBLE-BLINDED PLACEBO-CONTROLLED CLINICAL STUDY

PYOspot®



### Efficacy of a spot-on in dogs prone to localized superficial pyoderma relapses

*Dr. V. Fadok \*\*, Dr. C. Noli \*, Dr. E. Bensignor \*, Pr. R. S. Mueller \*, Pr. A. Oliveira \*, Dr. F. Seckerdiek*

\*ECVD dipl. - \*\*ACVD dipl.

Abstract published in **Veterinary Dermatology** (2020); 31 (suppl. 1), p.75 and poster presented at **2020 WCVD congress**.

#### INTRODUCTION

Dogs with skin disorders, particularly atopic dermatitis, may develop recurrent pyoderma. Although it is necessary to address the underlying cause, the treatment is not always sufficient to control recurrences. The purpose of this study is to evaluate the effects of a weekly application of a topical, PYOspot®, on reducing the frequency of pyoderma recurrences. Its formulation contains plant-extracted essential fatty acids and other natural ingredients, including essential oils known to balance the skin flora while providing purifying properties.

#### MATERIALS AND METHODS

28 dogs with at least 4 episodes of pyoderma in the previous year were included. Allergy treatments were allowed if the dogs had been treated for at least 3 months; allergen immunotherapy was allowed if started a year earlier. Antibiotics and additional topical treatments were allowed if there was a relapse during the study.

Dogs received either PYOspot® or a topical placebo applied once a week. The owners and veterinary dermatologists followed the protocol blindly, and the dogs were

randomly assigned to the two groups. Each dog was followed at least 4 times during the year of the study.

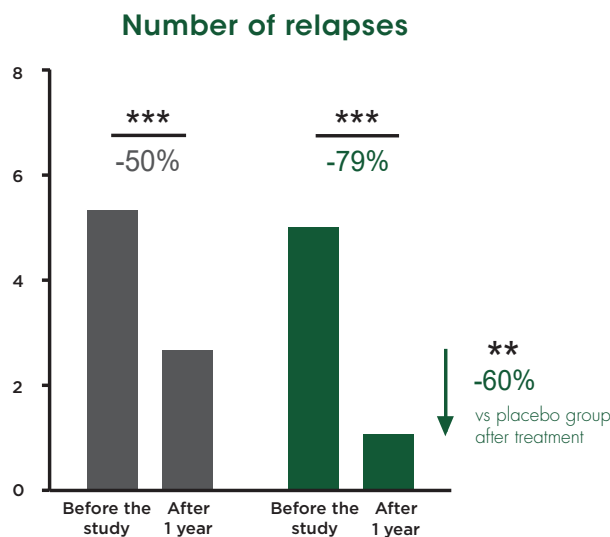
#### RESULTS

26 dogs completed the study among which 14 received PYOspot® and 12 received the placebo.

A significant reduction in the number of pyoderma occurrences was noted in both groups: -50% in the placebo group and -79% in the PYOspot® group. This reduction was significantly greater in the PYOspot® group ( $p=0.008$ ). The decrease in the placebo group is explained, according to the authors, by a more regular follow-up of the dogs during the study by veterinary dermatologists.

#### CONCLUSION

This study illustrates that the regular and long-term use of PYOspot®, in addition to medication, can help limit pyoderma relapses.




Statistical significance; \*\*,  $p < 0.01$  ; \*\*\*,  $p < 0.001$

# Efficacy of topicals containing essential oils and plant extracts compared to a chlorhexidine and miconazole-based shampoo on canine superficial pyoderma

Dr. C. Romero \*, Dr. G. Sheinberg \*, Dr. A.M. Cordero \*, Dr. R. Heredia

\*LACVD dipl.

Abstract published in **Veterinary Dermatology** (2020); 31 (suppl.1), p.44 and poster presented at **2020 WCVD congress**.



## INTRODUCTION

Superficial pyoderma is a common condition in dogs. As microbial resistance to antibiotics and antiseptics is a growing problem, natural topicals may be of therapeutic interest. Three natural products formulated with essential oils and plant extracts were compared to a shampoo containing chlorhexidine/miconazole and microsilver (Biohex®, Vetbiotek, USA).

## MATERIALS AND METHODS

30 dogs with clinical and cytological signs of superficial pyoderma were randomly divided into three groups:

- Group 1 : PYOclean® Shampoo twice a week and PYOclean® Mousse daily
- Groupe 2 : PYOclean® Shampoo twice a week and PYOclean® Spray daily
- Groupe 3: Biohex® Shampoo twice a week

Cytology, lesion and pruritus (PVAS) scores were assessed on days 0, 7 and 14.

## RESULTS

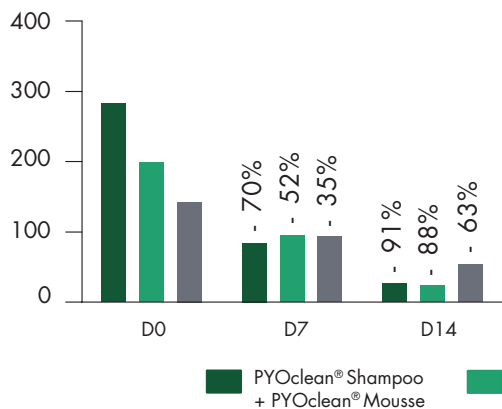
Cytological scores (extracellular cocci, yeast) and lesion scores were significantly reduced in all 3 groups at D7 and D14 ( $p < 0.05$ ), with no difference between the 3 groups.

Pruritus score was significantly reduced at D7 ( $p < 0.05$ ) for all 3 groups. It remained unchanged until D14 in group 3, while it further decreased in both groups 1 and 2 at D14, with a significant difference compared to Biohex® ( $p < 0.05$  for group 1 and  $p < 0.001$  for group 2 compared to group 3).

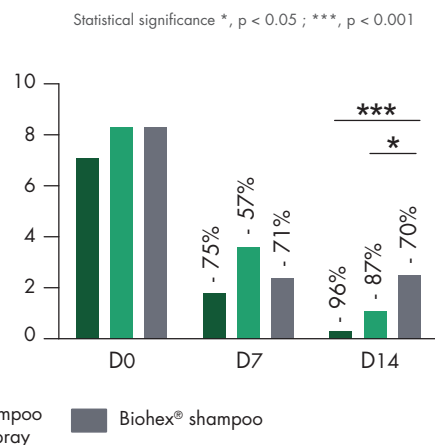
## CONCLUSION

This study highlights the value of using topical solutions containing natural purifying ingredients. These plant-based topicals can be considered as suitable options in the multimodal management of superficial pyoderma in dogs.

Lesion score



Pruritus score (PVAS)



# Kerato-seborrheic disorders

One can find under this term almost all epidermal anomalies involving:

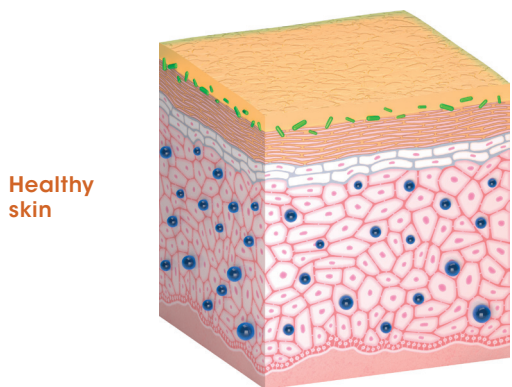
- 1 | An anomaly in the process of corneogenesis, characterized by abnormal exfoliation of corneocytes
- 2 | And/or abnormal sebum production [...]

They may be minor anomalies or actual dermatoses (ichthyosis for example). A single dermatose can cause dry or oily seborrheic keratosis depending on the case, and can change from dry to oily as the disease becomes chronic (e.g. FAD, sarcoptic mange...).[...]

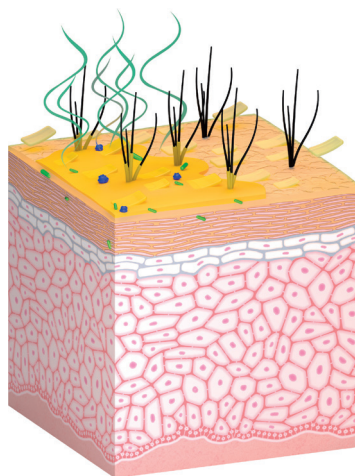
Various diseases can cause an unpleasant odor. The smell is linked to the secretion from various glands, especially sweat glands and sebaceous glands in domestic carnivores. Any alterations in these glands or their functioning, from genetic, endocrine or inflammatory origin, can be responsible for bad odors, possibly associated with changes in the skin appearance

and deterioration of the hydrolipidic film. [...] Bad odors or greasy skin could cause considerable embarrassment to pet owners and constitute thus their motivation for veterinarian consultations. Various dermo-cosmetic products designed to regenerate the skin surface by accelerating cell renewal are available.

From "Handbook of Veterinary Dermo-Cosmetics" by Dr. E. Bensignor and Dr. E. Vidémont  
Med'Com 2016



Healthy skin



Kerato-seborrheic skin

# Characterization of the cutaneous microbiota of malodor in dogs and effect of a spot-on on the microbiota

Dr. C. Meason-Smith, Dr. C. E. Older, Dr. R. Ocana, Dr. B. Dominguez, Dr. S. D. Lawhon, Dr. Jing Wu, Dr. A. Patterson\* and Pr. A. Rodrigues Hoffmann\*\*

\*ACVD dipl. - \*\*ACVP dipl.

Article published in **Veterinary Dermatology** (Dec. 2018); 29(6): p. 465-475 and Short Communication presented at **2017 NAVDF congress** in Orlando.



## INTRODUCTION

Malodor in animals is a frequent issue which can be embarrassing for pet owners. There are very few data available on the subject while in humans, studies have demonstrated a link between malodor and cutaneous microflora. The aim of this study was to compare the skin microbiota of dogs with or without strong body odor and to determine the potential effect of Essential 6<sup>®</sup> spot-on on the cutaneous flora.

## MATERIALS AND METHODS

27 bloodhound dogs were enrolled in the study and assessed as with or without strong body odor based on a mean malodor score from 0 (normal body odor) to 3 (severe malodor). They were then assigned to 3 groups:

- Control group with normal body odor
- Malodor group, weekly application of a placebo
- Malodor group, weekly application of Essential 6<sup>®</sup> spot-on

Dogs with strong body odor were randomly assigned to placebo or Essential 6<sup>®</sup> spot-on groups.

Surface skin swabs were collected from axilla and dorsum at inclusion and after 4 weeks for DNA extraction and sequencing using NGS (Next-Generation Sequencing). Additionally, quantitative PCR for *Malassezia spp.*, *Staphylococcus spp.* and *Staphylococcus pseudintermedius* were performed.

## RESULTS

NGS analysis demonstrated significant differences in bacterial communities between the 3 groups. At DO, dogs with strong body odor presented a reduced diversity of their skin microbiota with changes in certain bacterial taxa and increased abundances of *Malassezia spp.*, *Staphylococcus spp.*, *Staphylococcus pseudintermedius*, *Psychrobacter* and *Pseudomonas aeruginosa*.

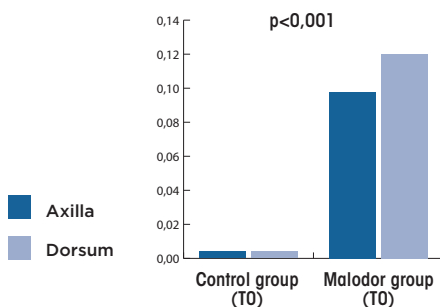
### After 4 weeks of treatment:

- Mean malodor score was significantly reduced in the Essential 6<sup>®</sup> spot-on group, but not in the placebo group ( $p < 0.05$ )
- A shift in bacterial community structure was observed in the Essential 6<sup>®</sup> spot-on group but not in the placebo group ( $p < 0.05$ )
- *Psychrobacter spp.* was less abundant in the dogs of Essential 6<sup>®</sup> spot-on group (-21%) whereas it was more abundant in dogs of the placebo group (+50%).

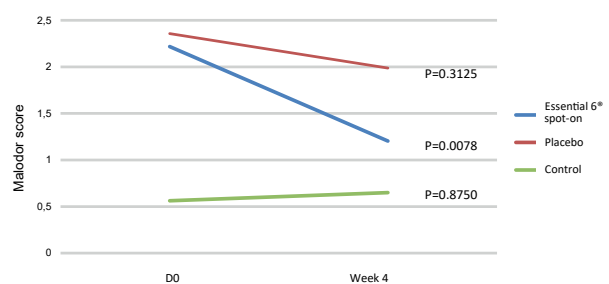
## CONCLUSION

Essential 6<sup>®</sup> spot-on significantly improves malodor in dogs with a direct effect on skin microbiota. Moreover, a novel association between cutaneous malodor and 2 bacterial genera, *Psychrobacter* and *Pseudomonas* was discovered in this study.

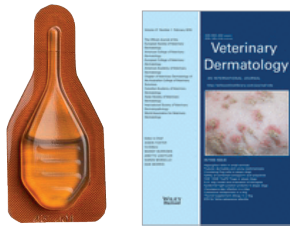
Median relative abundance of *Psychrobacter*



Change in malodor after 4 weeks



## CLINICAL CASES



## A case of sebaceous adenitis and mural folliculitis in a cat

Dr. K. Glos\*, Dr. S. Bettenay\*, Pr. R. S. Mueller\* & Dr. W. Von Bomhard.

\*ECVD dipl.

Article published in **Veterinary Dermatology** (Feb. 2016); 27(1), p. 57–e18.

### MEDICAL HISTORY AND TREATMENT

A 5-year-old castrated cat suffering from severe multifocal mural folliculitis and perifollicular dermatitis along with sebaceous adenitis was presented. After unsatisfactory results with antibiotics followed by oral EFA supplements and cleansing wipes, Essential 6<sup>®</sup> spot-on was proposed to the owner to bring EFA to the skin and for its ease of use.

### RESULTS

The cat responded with marked improvement within 1 month. After 6 months of sole application of Essential 6<sup>®</sup> spot-on, the cat showed an excellent clinical improvement with dense hair regrowth and a marked decrease in seborrheic dermatitis although periocular and perinasal scaling persisted.

This improvement was sustained for 12 months until a deep pyoderma occurred. The owner reported not to have applied Essential 6<sup>®</sup> spot-on for the previous 4 weeks. After a therapy leading to a rapid clinical improvement, Essential 6<sup>®</sup> spot-on was implemented again accompanied with ATOP 7<sup>®</sup> Spray, allowing the cat to remain clinically stable for another 18 months.

### CONCLUSION

This case demonstrates how Essential 6<sup>®</sup> spot-on, applied on a regular basis (here, during more than 3 years), can be considered in the management of sebaceous adenitis and to help improve skin conditions in this cat.

## A case of autosomal recessive congenital ichthyosis (ARCI) in a dog

Dr. C. Tamamoto-Mochizuki\*\*, Pr. T. Olivry\* et al.

\*ECVD/ACVD dipl. - \*\*AiCVD dipl.

Article published in **Veterinary Dermatology** (Aug. 2016); 27(4), p. 306–e75.

### MEDICAL HISTORY AND TREATMENT

A 6-month-old goldendoodle crossbred female dog was presented for excessive generalized scaling, which started at the age of 6 weeks. All examinations led to the diagnosis of an ARCI variant, confirmed by a genetic testing showing a mutation of the *PNPLA1* gene.

The initial weekly treatment with a moisturizing shampoo (HyLyt, Bayer) followed by a humectant conditioner (Humilac<sup>®</sup> Virbac), along with an oral essential fatty acid (EFA) supplement (Efa-Z<sup>®</sup> Virbac), showed mild improvement with persistence of a squamosis, sometimes severe, in particular on the dorsal area. A weekly application of Essential 6<sup>®</sup> spot-on was then added.

### RESULTS

5 months after, clinical improvements were observed even at the most severe dorsal area. 13 months after the initial presentation, the dog showed marked improvement with only mild scaling on her back and thighs. The owner reported that during this period of time, topical cares were temporarily discontinued for 2.5 weeks and the clinical signs were worsened regardless of the oral intakes. Skin lesions improved again as soon as topical treatments resumed. In order to determine if

the humectant (Humilac<sup>®</sup>, Virbac) was of help, application was discontinued.

Two months later, the owner reported that the skin lesions had not deteriorated, the humectant was thus withdrawn from the skin care protocol.

18 months after the initial presentation, the protocol combining an oral supplement twice a day with a weekly application of a topical EFA supplement, Essential 6<sup>®</sup> spot-on and a shampoo, resulted in a satisfactory control of the disease.

### CONCLUSION

A long-term combination of oral EFA and Essential 6<sup>®</sup> spot-on, a topical EFA supplement containing as well essential oils, appeared beneficial in this ARCI case. The application of Essential 6<sup>®</sup> spot-on was important since its temporary discontinuation resulted in case deterioration while resuming it enabled again a marked improvement. ARCI resulting in abnormalities of the *stratum corneum* lipids formation, the topical EFA supplement might be of interest in improving this skin condition. Reports of further ichthyosis cases treated in a similar way are necessary to determine which ARCI subsets would benefit from this combined treatment.

# Multicentric open study to assess the efficacy of a spot-on in domestic carnivores with kerato-seborrheic disorders

Dr. E. Bensignor\*, Dr. M. Nagata\*\* and Dr. T. Toomet  
 \*ECVD dipl. - \*\*AiCVD dipl.

Article published in **PMCAC** (2010); 45: p. 53-57.



## INTRODUCTION

The efficacy of Essential 6<sup>®</sup> spot-on was demonstrated through a large scale multicentric evaluation in 7 countries across 3 different continents under various climates and conditions.

## MATERIALS AND METHODS

The evaluations were assessed under veterinary supervision on 210 dogs and 79 cats. Each animal received a weekly application of Essential 6<sup>®</sup> spot-on during 4 weeks. 5 criteria were evaluated on dogs and 4 criteria on cats each week.

## RESULTS

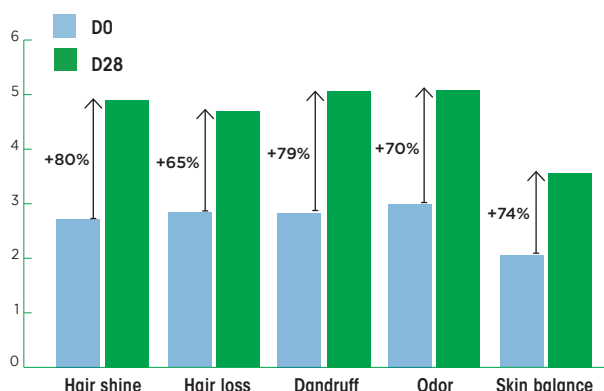
More than 80% of dogs and 70% of cats have presented remarkable and significant improvement ( $p < 0.0001$ ) of fur

shine, hair loss, scales, and skin dryness/greasiness balance as well as malodor improvement specifically in dogs.

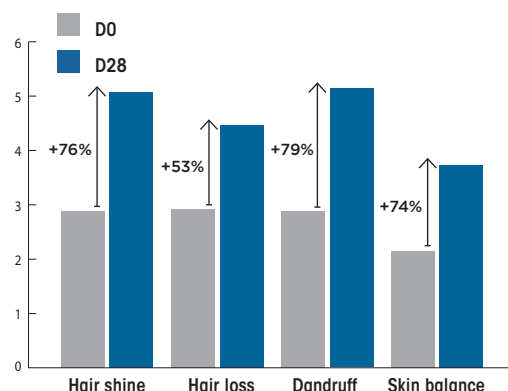
## CONCLUSION

This study conducted on a big number of dogs and cats shows that Essential 6<sup>®</sup> spot-on is an effective care to help improve skin and coat conditions. The results observed in this study are in accordance with previous studies published in France and in Japan from 2005 to 2009.

Scoring improvement in dogs



Scoring improvement in cats



## Publications since 2005

**Informations Dermatologiques Vétérinaires**  
 (IDV) 2005, 2006 & 2007 by  
 Dr. E. Bensignor *et al.*  
**Japanese Journal of Veterinary Dermatology**  
 (JJVD) in March 2009, vol. 15 p. 19-26 by  
 Dr. M. Nagata *et al.*



# Hyperkeratosis

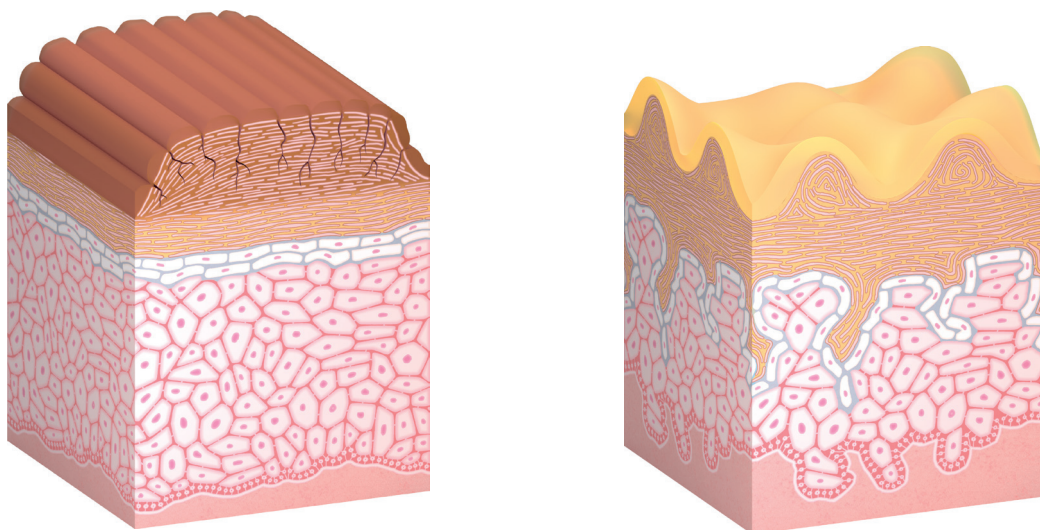
Hyperkeratosis refers to an increase in thickness of the *stratum corneum*.

This clinical presentation is found in some skin diseases and tends to affect certain locations, such as the nose, pads, elbows and pressure point areas (these are called "calluses"). Dermocosmetics play a major role in moisturizing the skin, reducing the size of the hyperkeratotic areas and avoiding common infectious complications, which can become problematic over time. It's recommended to apply moisturizing and mild

keratolytic active ingredients whose galenic form optimizes penetration into the thickened *stratum corneum*. They must be used regularly (at least once a day) to ensure a satisfactory efficacy.

From "**Handbook of Veterinary Dermo-Cosmetics**"  
by Dr. E. Bensignor and Dr. E. Vidémont  
Med'Com 2016

Different forms of hyperkeratosis



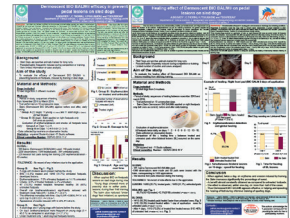# Protective and repairing efficacy of a natural balm on paws of sled dogs

Dr. A. Bouvier, Dr. C. Thorin, Pr. H. Pouliquen and Pr. P. Bourdeau\*

\*ECVD dipl.



Abstracts published in **Veterinary Dermatology** (2020); 31 (suppl.1), p.95 & 96 and 2 posters presented at **2020 WCVD congress**.  
 Doctoral veterinary thesis of Dr. A. Bouvier at École Nationale Vétérinaire de Nantes-Oniris (France)



## Protective effect

### MATERIALS AND METHODS

Dermoscent BIO BALM® was applied to the right paws of 30 sled dogs for 15 days, before and after daily training. The left paws served as controls. The presence of erythema/abrasion and cracks was assessed on days 1, 2, 4, 5, 8, 9, 12, 13 and 15.

### RESULTS

Among the 60 paws having received the balm, only 8 developed lesions, compared to 19 out of 60 control paws. The presence of erythema/abrasion and fissures was less frequent when the balm was applied: 7.3% and 0.5% respectively vs 14.1% and 2.3% in the control paws ( $p < 0.001$ ).

## Repairing effect

### MATERIALS AND METHODS

Dermoscent BIO BALM® was applied to the right paws of 30 sled dogs for 15 days, before and after daily training. The left paws served as controls. The presence of erythema/abrasion and cracks was assessed on days 1, 2, 4, 5, 8, 9, 12, 13 and 15. When bilateral erythema/abrasion type lesions occurred on the same day, the healing time was compared between treated paws with the balm and the control paws.

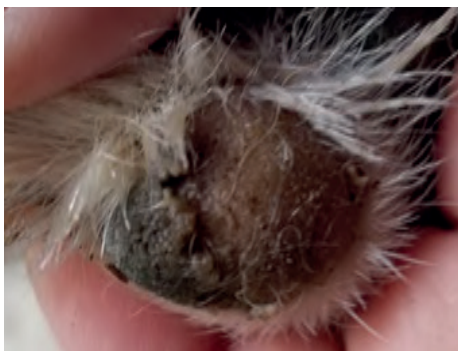### RESULTS

Among 15 bilateral lesions, 14 were repaired more rapidly with the balm. 53.3% of the lesions were repaired after 1 day of application versus 0% for the control paws ( $p < 0.001$ ). On D3, 73.3% of treated paws with the balm were repaired, versus 40% of the control paws ( $p < 0.001$ ).

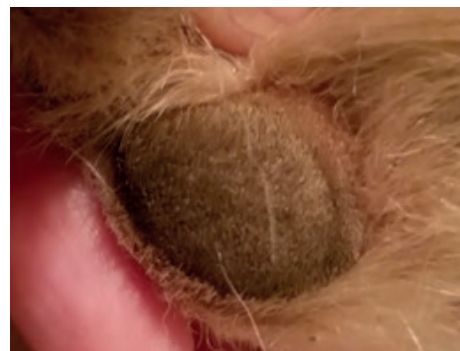## CONCLUSION

The balm was proven to be effective in protecting pads of intensively trained sled dogs by helping limit the occurrence of podal lesions. In addition, the balm helped promote faster repair of pads of these sportive dogs exposed to severe training conditions.


D0



D3



## RANDOMIZED, DOUBLE-BLIND, PLACEBO-CONTROLLED CLINICAL STUDY



### Control of idiopathic nasal hyperkeratosis in dogs with a natural balm

Pr. M-C. Cadiergues \*, Dr. C. Pressanti \*,  
Dr. M. Catarino & Dr. P. Mimouni

\*ECVD dipl.

Short Communication presented at **2015 ESVD congress** in Krakow and article published in **Veterinary Dermatology** (Apr. 2018); 29(2), p. 134-e53, open access. Doctoral veterinary thesis of Dr. M. Catarino at École Nationale Vétérinaire de Toulouse (France).

#### INTRODUCTION

Hyperkeratosis often results from defects in the process of corneogenesis. This affection, frequently encountered on noses of dogs, is often considered a cosmetic problem by pet owners. However, cracks may sometimes appear, increasing the risk of infection. Currently, practitioners lack proof of efficient and practical solutions to control this condition and prevent secondary infections.

The aim of this study was to investigate the efficacy of Dermoscent BIO BALM® in case of idiopathic nasal hyperkeratosis in dogs.

#### MATERIALS AND METHODS

The study was conducted over 2 months on 47 dogs suffering from idiopathic nasal hyperkeratosis randomly divided into two groups (39 ended the study). Either Dermoscent BIO BALM® or a placebo, composed of jellified water with occlusive properties, were applied once a day. 5 criteria were evaluated: lichenification, surface extent, skin dryness, nose suppleness and total score. Evaluation was made at D0, D30 and D60.

#### RÉSULTATS

Significant improvement ( $p < 0,05$ ) was observed on all five criteria from D30. The improvements on D60 for lichenification, surface extent, suppleness, dryness and total score were respectively -31.2%, -18.3%, -72.8%, -42.6% and -36.8% in the group of Dermoscent BIO BALM® ( $p < 0,05$ ) and -11.9%, +2.3%, -42.1%, -8% and -14% in the placebo group.


81% of the owners in the group of Dermoscent BIO BALM® were satisfied against 44% in the placebo group.

No major adverse reaction was reported.

#### CONCLUSION

This double-blind study shows the interest of Dermoscent BIO BALM® in dogs with idiopathic nasal hyperkeratosis. It can be recommended as a safe, long-term topical solution.

Before Dermoscent BIO BALM®



After Dermoscent BIO BALM®

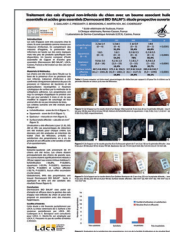

## Non-infected calluses in dogs: a prospective study

Dr. C. Pressanti\*, Pr. M-C. Cadiergues\*,  
Dr. E. Bensignor\* & Dr. E. Gaillard

\*ECVD dipl.

Short Communication presented at **2011 ESVD congress** in Brussels.  
Doctoral veterinary thesis of Dr. E. Gaillard at École Nationale Vétérinaire  
de Toulouse (France).



### INTRODUCTION

Pressure point calluses are common in dogs. They are considered as minor unless infected. In addition to hygienic measures, prevention and treatment are based on topical cares, yet very few specific products are available.

### MATERIALS AND METHODS

35 dogs were included and all with 1 or several non-infected calluses. Dermoscent BIO BALM® was applied once daily during 3 months by the owners. Each callus was evaluated with the following criteria: lichenification (score 0 to 4), scaling (score 0 to 4), thickness (in mm) and affected surface (in mm²).

### RESULTS

31 dogs completed the study (63 calluses). No adverse reaction was observed.

Scores were significantly reduced ( $p < 0.0001$ ) from D30 to D90 for all 4 criteria: lichenification, squamosis, thickness, area (table below).















Overall 94% of the owners found Dermoscent BIO BALM® as "easy to apply" and the final result was satisfactory for 83%.

### CONCLUSION

Dermoscent BIO BALM® is proven effective and safe to control non-infected calluses in dogs.

Mean +/-  $\sigma$  (min-max) scores, percentage of reduction from baseline of four criteria over the study period and p value of the Wilcoxon test

	D0	D30	D60	D90	p
Lichenification (0 - 4)	2,2 ± 1,4 (0 - 4)	1,5 ± 1 (0 - 4) <b>-31,5%</b>	1 ± 0,9 (0 - 3) <b>-55,4%</b>	1 ± 1 (0 - 2) <b>-66,8%</b>	< 0,0001
Squamosis (0 - 4)	1 ± 1 (0 - 4)	1 ± 1 (0 - 2) <b>-54,2%</b>	0,3 ± 0,5 (0 - 2) <b>-78%</b>	0,2 ± 0,5 (0 - 2) <b>-85,9%</b>	< 0,0001
Thickness (mm)	9,8 ± 3,6 (3,6 - 18)	8,2 ± 2,5 (2,5 - 15) <b>-16,4%</b>	7,1 ± 2,7 (2 - 15) <b>-26,8%</b>	6,8 ± 2,6 (0 - 15) <b>-30,7%</b>	< 0,0001
Total affected area (mm²)	467,4 ± 438,3 (61,2 - 2381,8)	375,1 ± 356,5 (32,9 - 1482,1) <b>-19,8%</b>	327,8 ± 314,0 (8,1 - 1127,5) <b>-29,9%</b>	289,4 ± 330,7 (5,9 - 1390) <b>-38,1%</b>	< 0,0001

SKIN AND COAT CONDITION	RECOMMENDATION	PROTOCOLS
<b>ALLERGY-PRONE SKIN</b> (pruritic, atopic, dry)	<div style="display: flex; justify-content: space-between;"> <div style="width: 45%;"> <p><b>HYGIENE</b></p>  <p>ATOP 7<sup>®</sup> Shampoo ATOP 7<sup>®</sup> Mousse ATOP 7<sup>®</sup> Wipes</p> </div> <div style="width: 45%;"> <p><b>CARE</b></p>  <p>ATOP 7<sup>®</sup> spot-on ATOP 7<sup>®</sup> Spray ATOP 7<sup>®</sup> MAX hydra ATOP 7<sup>®</sup> Hydra Cream</p> </div> </div>	<p>ATOP 7<sup>®</sup> spot-on: 1 pipette per week as long as necessary.            ATOP 7<sup>®</sup> Spray: once to several times a day to help manage pruritus.            ATOP 7<sup>®</sup> Hydra Spray: once to several times a week to hydrate.            ATOP 7<sup>®</sup> Hydra Cream: once or twice a day to hydrate localized hairless dry areas.</p> <p>ATOP 7<sup>®</sup> Shampoo: once to several times a week.            ATOP 7<sup>®</sup> Mousse: twice a week.            ATOP 7<sup>®</sup> Wipes: as often as necessary.</p>
<b>SKIN PRONE TO MICROBIAL IMBALANCES</b>	<div style="display: flex; justify-content: space-between;"> <div style="width: 45%;"> <p><b>HYGIENE</b></p>  <p>PYOclean<sup>®</sup> Shampoo PYOclean<sup>®</sup> Mousse PYOclean<sup>®</sup> Wipes</p> </div> <div style="width: 45%;"> <p><b>CARE</b></p>  <p>PYOspot<sup>®</sup> PYOclean<sup>®</sup> Spray</p> </div> </div>	<p>PYOspot<sup>®</sup>: 1 pipette per week as long as necessary to help limit relapses.            PYOclean<sup>®</sup> Spray: twice a day.</p> <p>PYOclean<sup>®</sup> Shampoo: once to several times a week.            PYOclean<sup>®</sup> Mousse: twice a week.            PYOclean<sup>®</sup> Wipes: hard-to-reach areas (skin folds, interdigital spaces...). As often as necessary.</p>
<b>AURICULAR HYGIENE</b>	 <p>Essential Oto<sup>®</sup> PYOclean<sup>®</sup> Oto</p>	<p>PYOclean<sup>®</sup> Oto: 1 dose per ear. In case of otitis externa: once a day before the medicated treatment. Maintenance: once a week.            Essential Oto<sup>®</sup>: regular hygiene of healthy ears. Once to twice a week.</p>
<b>KERATO-SEBORRHEIC DISORDERS</b> (greasy seborrhea, squamosis, hair loss, malodour...)	<div style="display: flex; justify-content: space-between;"> <div style="width: 45%;"> <p><b>HYGIENE</b></p>  <p>Essential 6<sup>®</sup> Sebo Shampoo Essential Mousse<sup>®</sup></p> </div> <div style="width: 45%;"> <p><b>CARE</b></p>  <p>Essential 6<sup>®</sup> spot-on</p> </div> </div>	<p>Essential 6<sup>®</sup> spot-on: 1 pipette per week for 2 months, and 1 pipette every 2 weeks after.</p> <p>Essential 6<sup>®</sup> Sebo Shampoo: once to several times a week.            Essential Mousse<sup>®</sup>: as often as necessary.</p>
<b>HYPERKERATINIZATION (Nose, calluses, pads) DAMAGED SKIN</b>	 <p>Dermoscent BIO BALM<sup>®</sup> Cicafolia<sup>®</sup></p>	<p>Dermoscent BIO BALM<sup>®</sup>: once to several times a day, as long as necessary.            Cicafolia<sup>®</sup>: once to several times a day as long as necessary.</p>
<b>AGING ANIMALS</b>	 <p>SILVER Massage Oil SENIOR Spot<sup>®</sup></p>	<p>SILVER Massage Oil: helps improve joint and muscle comfort, recommendations for use depending on the case.            SENIOR Spot<sup>®</sup>: Helps improve the well-being of senior animals prone to behavioral disorders. 1 pipette per week as long as necessary.</p>
<b>SUN PROTECTION</b>	 <p>SunFREE</p>	<p>Apply prior to exposure (hairless or depigmented areas, white-haired animals, photo-aggravated dermatitis...). Reapply in case of prolonged exposure or after bathing. Cleanse the area after exposure.</p>
<b>PHYSIOLOGICAL HYGIENE</b>	 <p>EFA Physio Shampoo</p>	<p>Once to several times a week.            Gentle shampoo adapted to the fragile skin of kittens and puppies.</p>
<b>STRESS AND RELATED SKIN DISORDERS</b>	 <p>Aromacalm<sup>®</sup></p>	<p>Renew the collar every month.</p>
<b>URINARY TRACT COMFORT</b>	 <p>Food supplement: Uti-Zen<sup>®</sup></p>	<p>Once daily as long as necessary.</p>
<b>HAIR LOSS FRAGILIZED CLAWS AND COAT</b>	 <p>Food supplement: Keravita<sup>®</sup></p>	<p>Once daily as long as necessary.</p>