

ケースレポート Case Report

Pyoderma

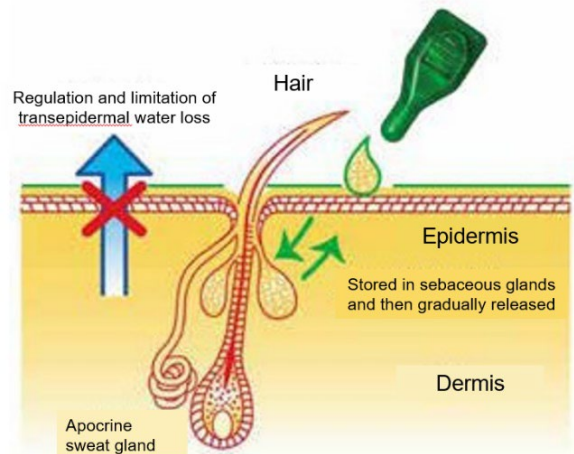
Author

Veterinary Specialists

Emergency Center

Dermatology • Otolaryngology

Chief Dr. Tomoya Hoshino



Discussion

Pyoderma is an infectious dermatosis caused by an overgrowth of staphylococci¹. *Staphylococcus pseudintermedius* and *S. schweifeli* are known as the causative bacteria. In recent years, multidrug-resistant *Staphylococcus pseudintermedius* (MRSP) has become a problem in the veterinary field as well as in the medical field. Therefore, antibiotics should be used carefully. *Staphylococcus pseudintermedius* is one of the constituent bacteria of the normal skin microflora, and in the development of chronic/recurrent pyoderma, the skin environment is the focus of attention. For the treatment of pyoderma, the (international) treatment guidelines^{2, 3} were created, and the Japanese Society of Veterinary Dermatology also created the treatment guiding principle⁴. In those guidelines, topical treatment with chlorhexidine or the administration of cephalexin is recommended as the first line treatment.

In the case presented below, none of the first line treatments were effective, and treatment with multiple antimicrobial agents didn't eliminate or alleviate the symptom, either. PYOspot[®] is a spot-on agent including the plant-derived essential fatty acids (omega 6 & 3) and the essential oils. The plant-derived essential fatty acid and the essential oils are expected to reinforce the skin barrier function and maintain the normal skin microflora, respectively. A previous randomized blinded trial with the spray consisting of essential oils and essential fatty acids⁵ demonstrated that the spray shortened the duration of antimicrobial therapy for pyoderma. In this case report, the use of PYOspot[®] without any other agents reduced the extent and number of skin rashes. (see the figures below)

The failure to achieve treatment of pyoderma by any of the other agents suggested that the skin environment was improved by PYOspot[®].

1. Small Animal DERMATOLOGY 7th Edition p198-214.
2. A.Hillier, DH Lyoid, JM Blondeau et al, Vet Dermatol 2012;5(3):163-e43.
3. L Beco,E, Guaguere E, C Lorente Mendez et al. Vet Rec 2013;19:72-78.
4. M Yamazaki, R Kano, K Harada et al. The Japanese journal of veterinary dermatology. 23 (3): 127-134, 2017
5. E Bensignor, L Fabriès, L Bailleux. Vet Dermatol . 2016;27(6):464-e123

※ [Clinical Training Clinics designated by the Minister of Agriculture, Forestry and Fisheries]

VSEC is a secondary animal care vet clinic, located in Kawaguchi, Saitama Prefecture.

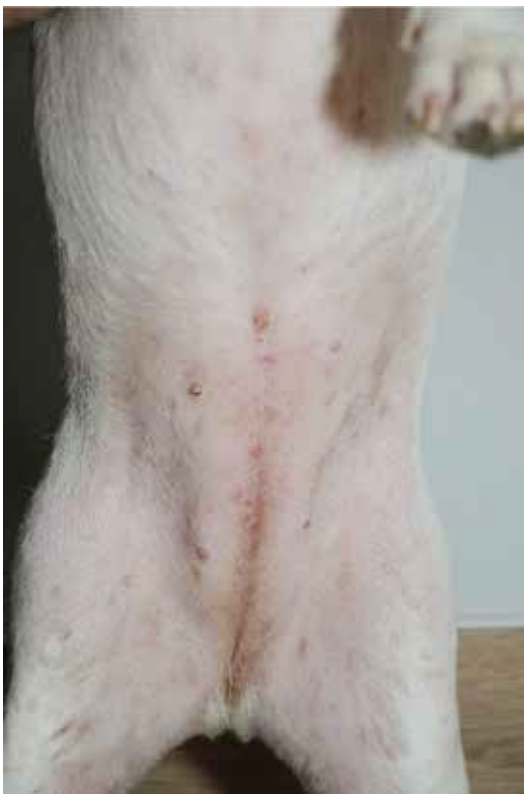[Address] 815, Ishigami, Kawaguchi, Saitama

[Contact] specialized medical service : 048-229-7390 emergency medical care : 048-229-7299

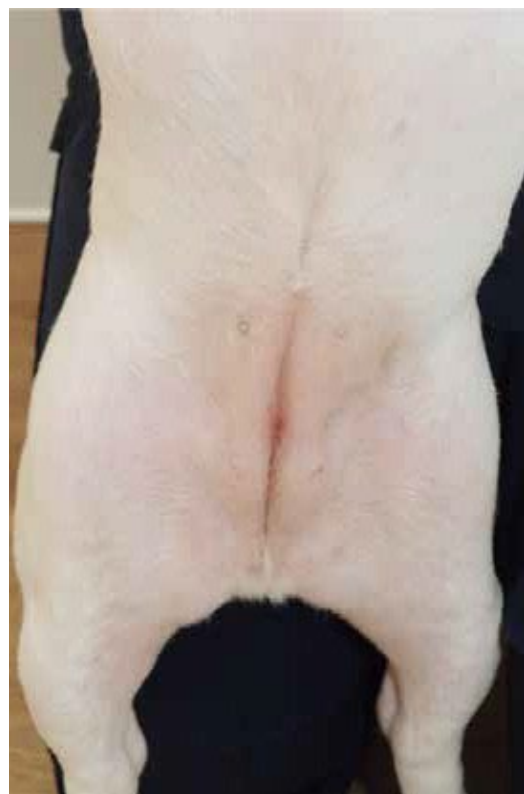Case 1 French bulldog 2 years old, spayed female Date of 1st visit : 22/10/2023

In April 2023, the dog visited the primary care vet with a complaint of papules, erythema, and pruritus almost all over the body. As the symptoms did not improve with cefovecin sodium (Convenia[®], Zoetis), allergic dermatitis was suspected and prednisolone (Prednisone Tablets, Shionogi Pharma, Osaka, Japan) was administered. Thereafter, the dog didn't receive any treatments, and at a return visit in July, it was observed that her skin rash had worsened. After 2 weeks of treatment with pradofloxacin (Veraflox Tablets, Elanco Japan, Tokyo) and prednisolone, prednisolone was withdrawn and minocycline (Minocycline Tablets, Towa Pharmaceutical, Osaka, Japan) was added instead of pradofloxacin due to lack of improvement, and then the dog was referred to our clinic .

Physical evaluation at the first visit indicated scattered papules and erythema mainly in the midline of the abdomen (picture 1).The analysis of a sample from the affected area showed an image of phagocytic cells phagocytosing gram-positive cocci. Bacterial culture test detected MRSP (minocycline susceptible). The dog was diagnosed with superficial spreading pyoderma. I also took into consideration the immature skin barrier function as a predisposing factor. The use of Dermoscent PYOspot[®] (“PYOspot[®]”) was indicated twice a week. The extent and number of skin rashes decreased on November 5, and no increase was observed after the PYOspot[®] use was suspended (picture 2).



picture 1 (22/10/2023)



picture 2 (2/11/2023)

Case Report

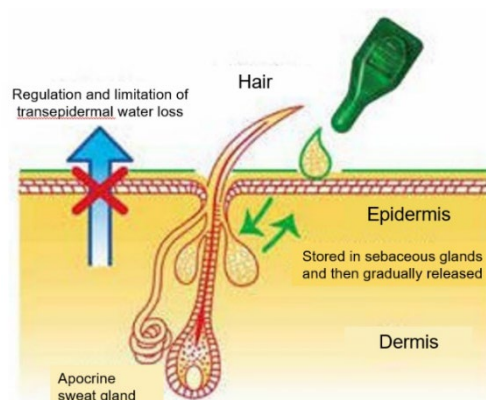
Pyoderma

Author

**Veterinary Specialists
Emergency Center**

Dermatology • Otolaryngology

Chief Dr. Tomoya Hoshino



Case 2 Miniature Pinscher 18 years old, neutered Date of 1st visit 11/2023

The dog presented with generalized alopecia, scaling, and erythema since September 2022. While the dog was administered cefovecin sodium (Convenia®, Zoetis Japan, Tokyo) subcutaneously every two weeks from January 2023 to April 2023, there was little improvement. From May 2023 to December 2023, shampooing was carried out for the dog every two weeks using 2% chlorhexidine acetate, but no significant improvement was observed. From September 2023 to November 2023, the dog was treated with Fosfomycin 7mg/kg BID (Fosmicin tablets 250mg, Meiji Seika Pharma, Tokyo), but no improvement was observed, and the dog was referred to our hospital.

On our initial physical evaluation, diffuse erythematous hair loss and scaling were observed on the trunk (Figure 1). The dog was diagnosed with superficial spreading pyoderma and metabolism (hypothyroidism, endogenous glucocorticoids) as an exacerbation factor was examined. Cytology revealed phagocytosis of Gram-positive cocci being phagocytosed. The results of both Wood's lamp test and fungal culture were negative. No notable findings were observed in the blood tests.

On the 20th of December 2023, I stopped using shampoo and started applying Dermoscent PYOspot® once a week. Two months after start its use (Figure 2), the rash was almost completely healed. Since then the Dermoscent PYOspot® has been applied once a week as a preventive measure and no obvious abnormalities have been observed.

Figure 1: Partial irregular patches of hair loss were observed on the entire body, along with scales and red spots.

Figure 2: Hair loss, scaling, and erythema have disappeared.



Figure 1

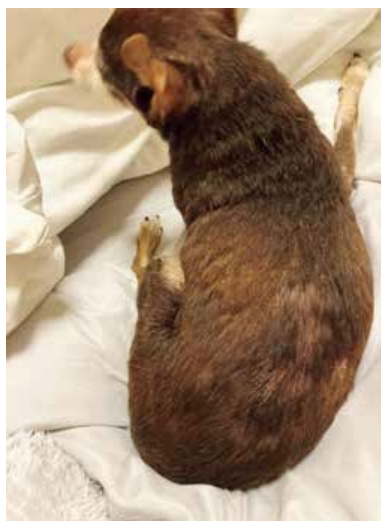

Figure 2

Discussion

To treat the so-called pyoderma¹, which results from the excessive proliferation of staphylococci, I consider that the balance of the skin microbiota is important. In human medicine, detailed research reports have been published on the skin microbiota. Previous reports have indicated age-related skin microbial dysbiosis^{2,3}. It is suggested that the skin of human adults harbors a greater diversity of *Staphylococcus* species (enrichment of *Staphylococcus*) than that of elderly people, and it is considered to play a role in maintaining the barrier function of the skin. In this case, I speculated that skin dysbiosis would occur in a similar manner to that observed in humans, given the dog's advanced age of 18. When antibacterial treatment was discontinued and treatment was shifted to restoring the balance of the skin microbiota, the exanthema improved rapidly. This suggests a corrective effect of Dermoscent PYOspot® on the balance of the skin microbiota. In this case, no recurrence of exanthema has been observed after continuing preventive use of Dermoscent PYOspot® after the exanthema had almost completely healed, suggesting that antibacterial treatment might not be necessary. As no apparent adverse effects such as redness and itch have been observed at the application site of Dermoscent PYOspot®, I realize that the formulation is safe for long-term use.

Incidentally, the overuse of antibacterial agents has long been a concern in the field of medicine, including veterinary medicine. In the field of veterinary medicine, antibacterial guidelines^{4,5,6} for pyoderma classify antibacterial agents into three categories: 1st tier, 2nd tier, and 3rd tier. Fosfomycin used in this case is belong to 3rd tier. Antibacterial agents classified as 3rd tier including vancomycin, and their use is basically prohibited in veterinary medicine, considering their use as a treatment option for severe bacterial infections in human medicine. In this case, neither bacterial culture nor antimicrobial susceptibility testing was conducted, and topical treatment with chlorhexidine acetate was also ineffective. When exanthema do not improve with cephem antibiotics or chlorhexidine-based shampoos like this case, it is crucial to avoid the abuse of antibacterial agents.

References

1. Muller & Kirks Small animal dermatology 7th edition p198-214.
2. Paromital and Satya P. *Nutrients* 2021(13):4550.
3. H H-J Kim, JJ Kim, NR Myeong et al. *Sci. Rep.* 2019(9): 16748.
4. A Hillier, DH Lyoid, JM Blondeau et al, *Vet Dermatol* 2012;5(3): 163-e43.
5. L Beco, E, Guaguere E, C Lorente Mendez et al. *Vet Rec* 2013(9):72-78.
6. M Yamazaki, R Kano, K Harada et al. *The Japanese Journal of Veterinary Dermatology* 23 (3): 127–134, 2017

※ [Clinical Training Clinics designated by the Minister of Agriculture, Forestry and Fisheries]

VSEC is a secondary animal care vet clinic, located in Kawaguchi, Saitama Prefecture.

[Address] 815, Ishigami, Kawaguchi, Saitama

[Contact] specialized medical service: 048-229-7390 emergency medical care: 048-229-7299

WARNING : antibiotics mentioned in these case reports : Cefocefiv, Pradofloxacin and Cefovecin are critically important antimicrobials. An antibiogram must be performed before prescribing, delivering or administering these antibiotics. Critically important antimicrobials should be used as a last resort.